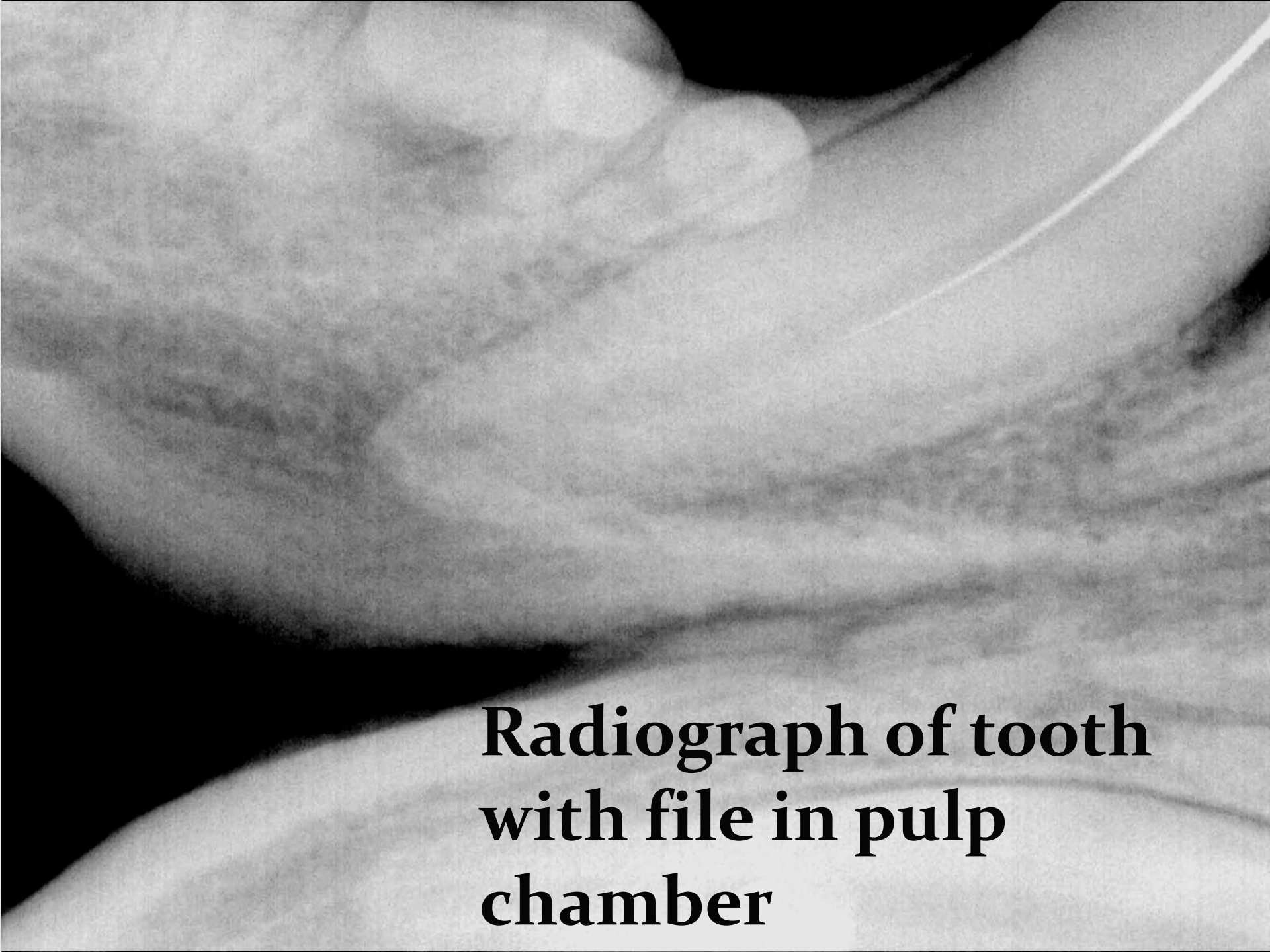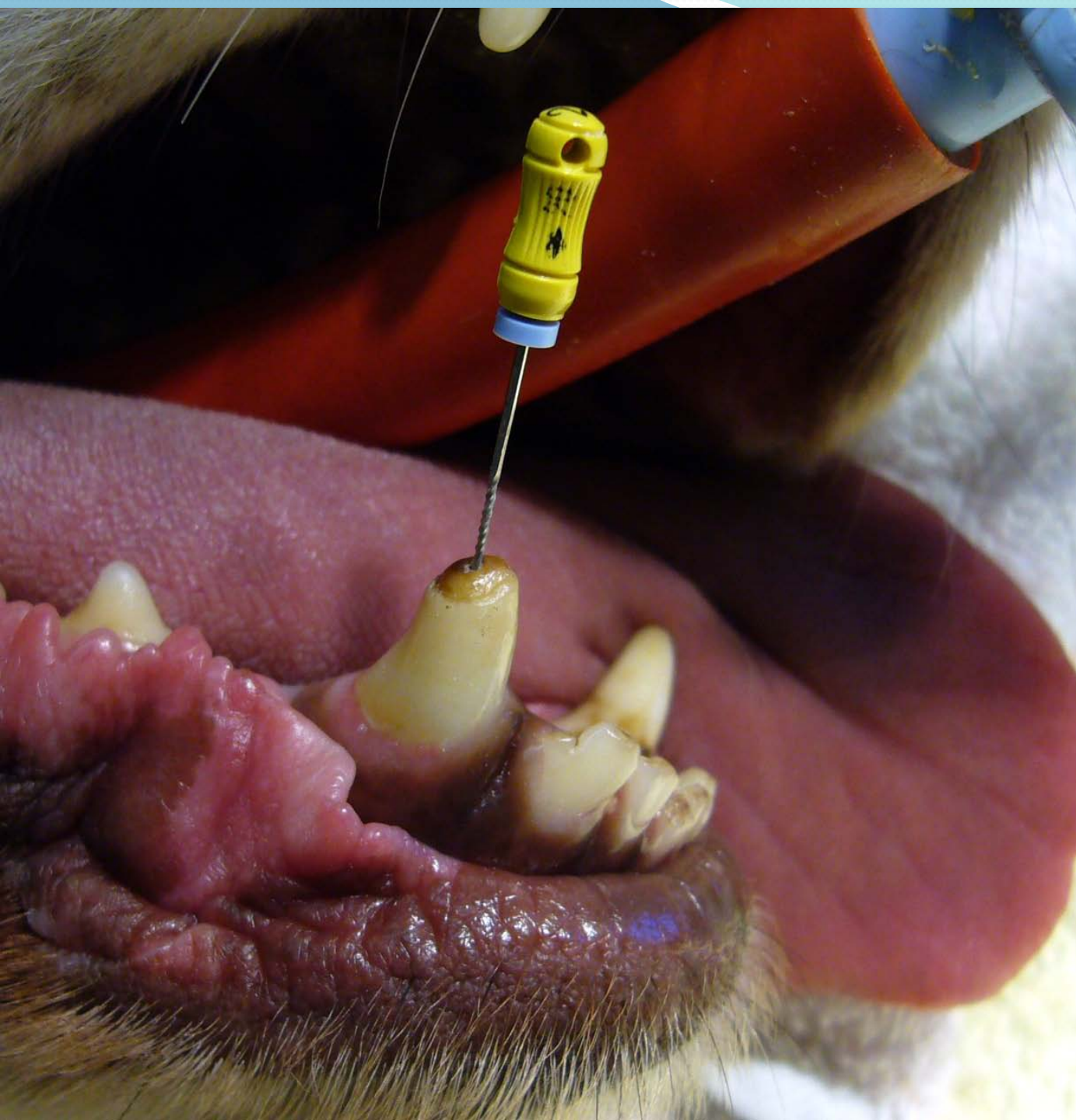


Fractured Canine Tooth

Root Canal Therapy



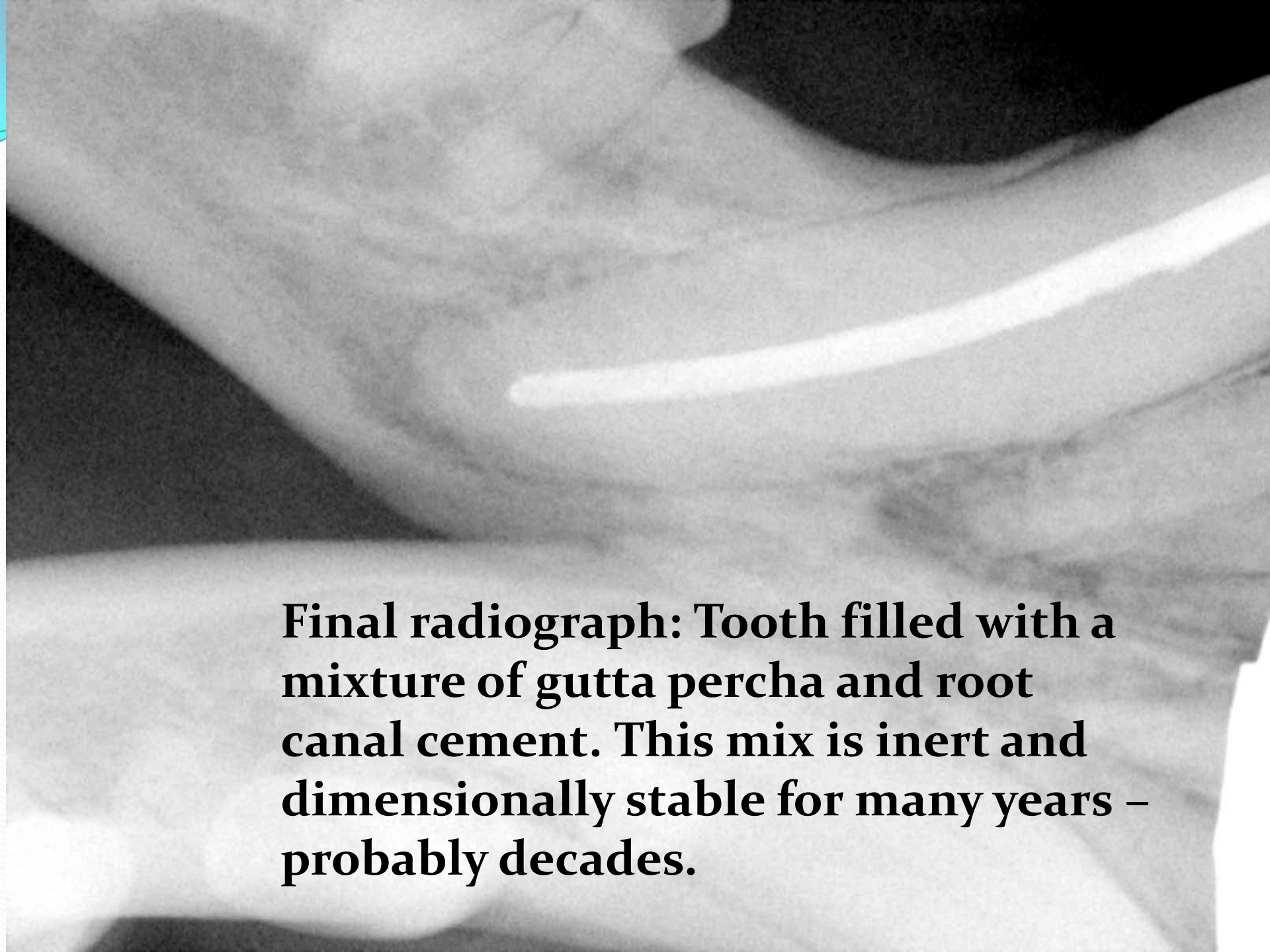
**Fractured
right lower
canine
with
file in
open pulp
access**

A black and white radiograph of a tooth. The image shows the internal pulp chamber and root canal. A thin, dark line representing a file is visible within the pulp chamber. The surrounding bone structure is visible as lighter gray areas.

**Radiograph of tooth
with file in pulp
chamber**

A close-up, black and white photograph of a dental procedure. The image shows the interior of a root canal with several dental files of varying sizes. A large file is positioned at the top, and a smaller file is positioned below it. The text is overlaid on the bottom right of the image.

**Largest file to reach
the full working
length of root canal**



Final radiograph: Tooth filled with a mixture of gutta percha and root canal cement. This mix is inert and dimensionally stable for many years – probably decades.